

RESEARCH ARTICLE

Effects of Sambiloto (*Andrographis paniculata*) Extract and Spirulina (*Spirulina platensis*) Administration on Ki-67 Protein Expression in the Colon Epithelial Cells of *Plasmodium berghei*-infected Mice

Kusmardi Kusmardi^{1,2,3,4}, Bagas Ariffandi⁵, Nadar Sukri Lubis⁶, Tri Wahyuni Lestari⁷, Putri Reno Intan⁸, Alfred Pakpahan^{9,10*}

¹Anatomical Pathology Department, Faculty of Medicine, Universitas Indonesia, Jl. Salemba Raya No.6, Jakarta 10340, Indonesia

²Drug Development Research Cluster, Indonesia Medical Educational and Research Institute, Jl. Salemba Raya No.6, Jakarta 10340, Indonesia

³Human Cancer Research Cluster, Indonesia Medical Educational and Research Institute, Jl. Salemba Raya No.6, Jakarta 10340, Indonesia

⁴Doctoral Program in Biomedical Sciences, Faculty of Medicine, Universitas Indonesia, Jl. Salemba Raya No.6, Jakarta 10340, Indonesia

⁵Undergraduate Program, Faculty of Medicine, Universitas Indonesia, Jl. Salemba Raya No.6, Jakarta 10340, Indonesia

⁶Parasitology Department, Faculty of Medicine, Universitas Indonesia, Jl. Salemba Raya No.6, Jakarta 10340, Indonesia

⁷National Institute of Health Research and Development, Ministry of Health of Indonesia, Jl. Percetakan Negara No.29, Jakarta 10560, Indonesia

⁸Centre for Research and Development of Biomedical and Basic Health Technology, National Institute of Health Research and Development, Ministry of Health, Jl. Percetakan Negara No.29, Jakarta 10560, Indonesia

⁹Oral Biology Department, Faculty of Dentistry, Universtas Trisakti, Jl. Kyai Tapa No. 260, Jakarta 11440, Indonesia

¹⁰Biology Department, Faculty of Medicine, Universitas Trisakti, Jl. Kyai Tapa No. 260, Jakarta 11440, Indonesia

*Corresponding author. E-mail: alfred@trisakti.ac.id

Received date: Oct 22, 2021; Revised date: Jan 25, 2022; Accepted date: Feb 2, 2022

Abstract

BACKGROUND: Malaria remains a global health concern and an endemic disease in Indonesia. Sambiloto (*Andrographis paniculata*) and spirulina (*Spirulina platensis*) are two potential antimalarial agents which act as antioxidants and antiinflammatories that can suppress morbidities during chronic inflammation in malaria, such as proliferation in the colon. This study aims to investigate the effects of *A. paniculata* extract and *S. platensis* administration on Ki-67 expression in medial colon epithelial cells of *Plasmodium berghei*-infected mice measured by H-score.

METHODS: Thirty *P. berghei*-infected male Swiss-Webster mice were divided into five groups: negative controls (carboxymethyl cellulose/CMC); positive controls (dihydroartemisinin-piperazine/DHP); *A. paniculata* extract alone (AP); *A. paniculata* extract in combination with *S. platensis* extract (AP+ES); and with *S. platensis* powder (AP+PS). All mice were infected with *P. berghei*

on day 0. The treatment for each group were given 3 days before infection (D-3) until the day of infection (D0) for 28 days after infection. Colon tissues were processed with immunohistochemistry to detect Ki-67.

RESULTS: A difference in Ki-67 expression was observed among the groups ($p < 0.01$). The mean H-score for the CMC control group is 135.503 ± 6.723 . The lowest level of Ki-67 expression was observed in the AP+PS group (H-score = 110.941 ± 7.079). AP group did not show a significant difference from the CMC group ($p = 0.514$) and neither did the AP+ES group ($p = 0.234$).

CONCLUSION: In conclusion, administration of *A. paniculata* extract and *S. platensis* powder lowers Ki-67 expression in medial colon epithelial cells of *P. berghei*-infected mice.

KEYWORDS: malaria, spirulina, Ki-67, *Andrographis paniculata*, *Spirulina platensis*

Indones Biomed J. 2022; 14(1): 84-90

Introduction

Malaria, a parasitic disease caused by *Plasmodium sp.* infection, has a high mortality rate and remains one of the world's health problems. Over 200 million cases with more than 400,000 deaths happened worldwide in 2017.(1) In Indonesia, malaria is still an endemic disease in several districts and cities, especially those located in the eastern territories. Based on the Annual Parasite Incidence (API), the national morbidity rate reaches 0.85.(2)

Apart from causing anemia, *Plasmodium sp.* also induces fever and systemic inflammatory responses in various organs of the body. The colon is one of the organs that often experiences inflammation during an infection and is prone to undergo the process of dysplasia since persistent or repeated exposure to inflammation makes cells more susceptible to changes in structure and function.(3,4) Currently, Artemisinin-based Combination Therapy (ACT) is the standard treatment for malaria.(1,5) However, the current trend indicates increasing cases of resistance to artemisinin and other antimalarial drugs.(6-8) Therefore, new policies and therapeutic approaches are needed in the management of malaria to not only eradicate the parasite, but also suppress the inflammatory consequences that arise. Indonesians often use plant-derived traditional medicines to treat various diseases. *Spirulina (Spirulina platensis)* and *sambiloto (Andrographis paniculata)* are two types of herbal ingredients that have potential as curative agents against malarial infection.(9-12) *S. platensis* is a microalgae that is known to contain high nutritional value and has good hypolipidemic, antioxidant, and anti-inflammatory properties.(9,10) Meanwhile, *A. paniculata* is a plant species that has been widely used for the treatment of various diseases including malaria in Africa, America and Asia. Compounds derived from *A. paniculata* extract have antimicrobial, cytotoxic, anti-inflammatory, antioxidant, and immunostimulatory properties.(11,12)

In a previous study, administration of *A. paniculata* and *S. platensis* extracts was able to reduce the level of parasitemia and increase the number of erythrocytes and hemoglobin level in an experimental test on mice.(13) In addition, the combination of the extracts also significantly reduced the amount of angiogenesis and inflammatory foci in the colonic epithelial tissue.(4) However, this study only investigated the effects histopathologically. The efficacy of this treatment needs to be confirmed with more accurate indicators such as using biological markers. One of the proteins that can be used as a prognostic factor is the Ki-67

protein, which acts as a marker for cell proliferation.(14) Ki-67 has a role in the process of cell proliferation so that it can be used as a marker of hyperplasia and dysplasia that occurs in systemic inflammatory conditions such as malaria. Therefore, we are interested in further investigating the effect of *A. paniculata* and *S. platensis* extracts administration on colonic epithelial cell proliferation as a result of prolonged inflammation in malarial infection through the measurement of the Ki-67 protein.(15) The purpose of this study was to determine the effect of *A. paniculata* and *S. platensis* extracts administration on the expression of Ki-67 in epithelial cells of the medial colon in mice. In addition, it was also necessary to assess the effectiveness of *A. paniculata* and *S. platensis* combination compared to *A. paniculata* extract alone. Two dosage forms of *S. platensis*, namely crude powder and extract preparation, also need to be compared due to potential differences in substance solubility.

Methods

Subjects Treatment

This study was an experimental study using stored biological materials in the form of colonic tissue blocks from a previous study.(16) In this study, 30 male mice of Swiss Webster strain were divided into five test groups as independent variables, which consisted of : 1) a negative control group given sodium carboxymethylcellulose solvent (CMC), 2) a positive control group given dihydroartemisinin and piperazine combination (DHP) at a dose of 195 mg/kgBW, 3) a test group that was given *A. paniculata* extract alone with a concentration of 70% and a dose of 200 mg/kgBW (AP), 4) a test group that was given a combination of *A. paniculata* extract and *S. platensis* extract with a concentration of 80% and a dose of 130 mg/kgBW (AP+ES), and 5) another test group that was given a combination of *A. paniculata* extract and *S. platensis* powder at a dose of 26 mg/kgBW (AP+PS).

The *S. platensis* extract and powder and the *A. paniculata* ethanol extract were obtained from Parasitology Laboratory, National Institute of Health Research and Development, Indonesian Ministry of Health, Jakarta, Indonesia. The dosage of these substances was determined based on the safe dose from toxicity tests in previous studies.(17-19)

All mice were infected with *P. berghei* on day 0. Each animal was injected with 0.1 mL of parasite suspension intraperitoneally. Parasitemia level was measured through microscopic observation of peripheral blood sample after 5

days. Plasmodium infection was confirmed by parasitemia level of at least 30%. Herbal treatments were given 3 days prior (D-3) to the day of parasite induction (D0) and continued for 28 days after. Colons were then harvested and stored in the form of paraffin blocks. The tissue blocks were then processed immunohistochemically and observed under a light microscope. The Ki-67 expression was quantified in the form of H Score as the dependent variable.

Immunohistochemistry

The colonic tissues embedded in the paraffin blocks were cut into 4 µm thick slices, placed on a slide, and coated with poly-L-lysine. Tissue section was incubated with Ki-67 antibody was carried out at 100 times dilution in serum at room temperature for 60 minutes. Then, the preparations were washed with Phosphate Buffered Saline (PBS) for 10 minutes, incubated with secondary antibody universal link, and washed for another 10 minutes. Then the preparations were incubated with trecavidin-HRP, washed with PBS twice, and given diaminobenzidine (DAB) as chromogen. After being washed with running water, the preparations were soaked in Lilie Mayer haematoxylin as a counterstain and then washed again. After staining, the preparations were soaked in lithium carbonate, washed, dehydrated with ethanol, and rinsed with xylol. The finished preparations were then covered with aqueous mounting media and ready for observation.

Quantification of Ki-67 Protein Expression

Each preparation was observed using a light microscope at 400 times magnification and documented by a camera. Each preparation was observed in 5 visual fields which were judged as adequate (minimal contaminants, no dye droplets,

and no folded or damaged tissue). Preparations that did not contain enough adequate visual fields were excluded from the observation. The expression for Ki-67 was determined by the percentage of cells with very brown (+++), brown (++), slightly brown (+), and blue (-) cells in color. Percentages were measured using the IHC Profiler feature of the ImageJ® application (National Institutes of Health, Bethesda, MD, USA). The levels were then expressed in H score with the calculation formula of : $H\ Score = \% (-) + 2\ x\ \% (+) + 3\ x\ \% (++) + 4\ x\ \% (+++)$, {the percentages ranges 0%-400%}. Prior to the measurement, the images were processed by cropping the background, connective tissues, and contaminants in order to reduce bias.

Data Analysis

Data was analyzed using the IBM SPSS Statistics® version 26 (IBM Corporation, Armonk, NY, USA). A normality test was performed using the Shapiro-Wilk test. After that, Levene test was performed to assess variance homogeneity. Because the Ki-67 expression data were distributed normally ($p > 0.05$), a parametric test was carried out to challenge the hypothesis. The parametric test used was one-way Anova. The analysis was continued with post-hoc Tukey's HSD test to determine which groups were significantly different ($p < 0.05$).

Results

The result of the normality test on the H-Score of Ki-67 expression on 27 samples showed normal data distribution ($p > 0.05$). Figure 1 showed the distribution of the Ki-67 expression data per test group.

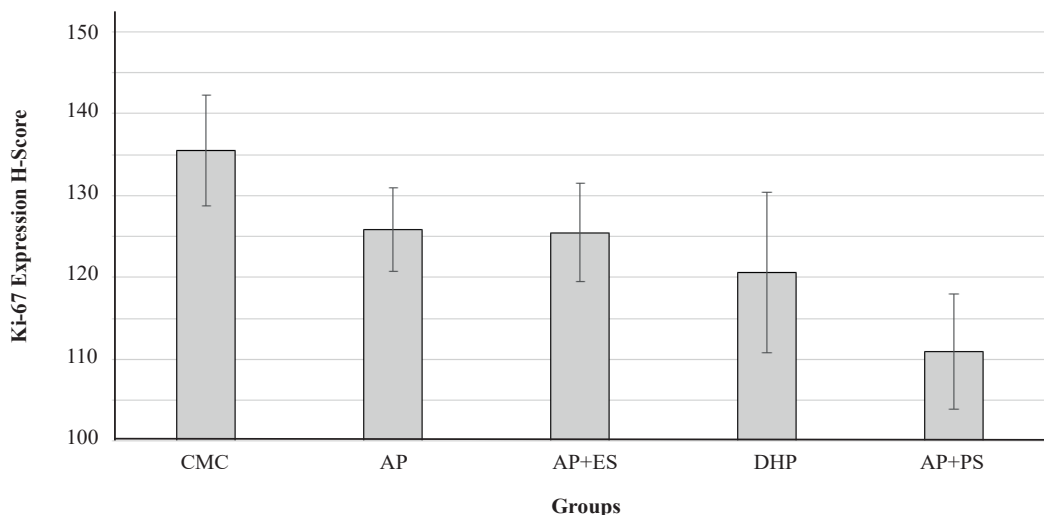


Figure 1. Bar chart of mean H-score of Ki-67 expression in each test group with standard deviation as the error bar.

Table 1. H-score of Ki-67 expression for each test group.

Test Group	Mean±SD	p-value
Carboxymethyl cellulose (CMC)	135.030±6.723	
<i>A. paniculata</i> extract (AP)	128.851±5.129	
AP and <i>S. platensis</i> extract (AP+ES)	125.480±6.015	0.001
Dihydroartemisinin piperazine (DHP)	120.589±9.763	
AP and powder <i>S. platensis</i> (AP+PS)	110.941±7.079	

The average H-score for the Ki-67 expression as a whole was 124.677% with a standard deviation of 10.737%. The highest mean value was observed in the solvent control group which was given CMC, while the lowest mean value was observed in the treatment group given *A. paniculata* extract and *S. platensis* powder combination (AP+PS). Descriptive data of Ki-67 expression in each group were listed in Table 1.

Based on the one-way Anova test, there was a significant difference in the mean H-score of Ki-67 expression among the five test groups ($p < 0.01$). The results of Tukey's HSD test to compare the mean H-score of Ki-67 expression between groups are listed in Table 2.

Significant mean difference was observed between the solvent control group (CMC) and the treatment group given dihydroartemisinin-piperazine (DHP) and the test group given combination of *A. paniculata* extract and *S. platensis* powder (AP+PS) with $p < 0.05$. Meanwhile, the mean of the group given *A. paniculata* extract alone (AP) and the group given the combination of *A. paniculata* extract and *S. platensis* extract were not significantly different from the CMC control group ($p > 0.05$). Significant differences were also found between the AP group and the AP+PS group and between the AP+ES and AP+PS groups ($p < 0.05$).

Figure 2 showed the comparison of sample preparations under a light microscope with a 400 times magnification with qualitatively negative and low positive results. On negative results, the cytoplasm and nucleus of the epithelial cells appeared pale bluish. Meanwhile, on preparations with low positive results, the cytoplasm and nucleus appeared

brown. Comparison among the five experimental groups was shown in Figure 3. CMC preparations, which have the highest level of Ki-67 expression, appeared brown, while AP+PS preparations with the lowest level showed pale and bluish color.

Discussion

The group of mice given DHP therapy as a positive control at a dose of 195 mg/kgBW/day for four days had a significantly lower Ki-67 expression than the control group given CMC solvent ($p = 0.013$). This is consistent with DHP function as the first-line malaria treatment.(20) As the infection subsides, the inflammation and proliferation process in the epithelial tissue of the mice colon decreases so that the expression of Ki-67 also declines. In this study, Ki67 expression was observed in non-inflammatory colonic epithelial cells. It is known that an increase in the number of inflammatory cells can trigger colon carcinogenesis.

A. paniculata contains several active metabolites, including andrographolide, which are effective as antiparasitic and anti-inflammatory agents.(21,22) In theory, the AP group should show lower Ki-67 expression compared to the CMC control group. However, the mean difference observed in this study was not statistically significant. These findings are in line with the histopathological findings of the previous.(4) In their study, administration of *A. paniculata* extract significantly reduced the number of inflammatory foci in the colonic epithelial tissue. But, there were no

Table 2. The results of the p-value of Tukey's HSD Test of Ki-67 expression between groups.

	CMC	AP	AP+ES	DHP	AP+PS
CMC	1	-	-	-	-
AP	0.514	1	-	-	-
AP+ES	0.234	0.949	1	-	-
DHP	0.013	0.305	0.829	1	-
AP+PS	<0.01	<0.01	0.046	0.213	1

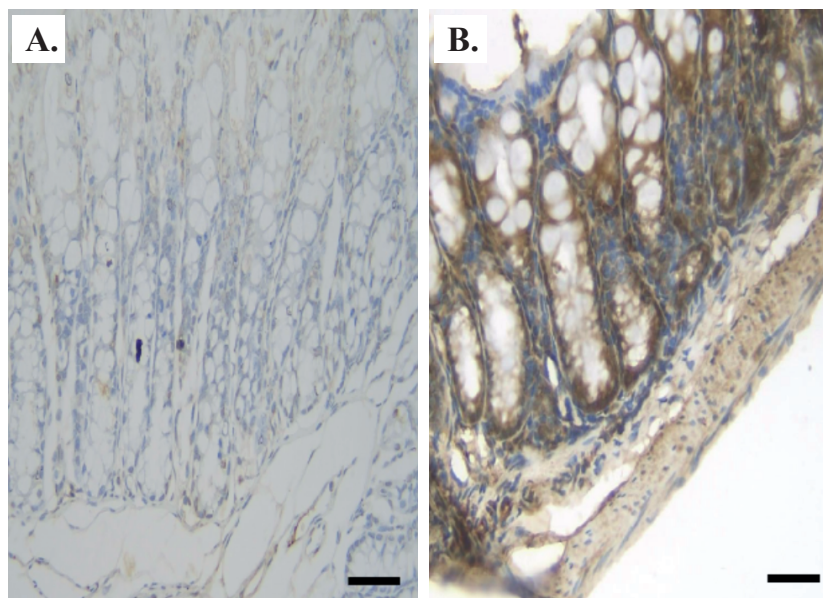


Figure 2. Comparison of preparations with qualitatively negative (A) and high positive result (B). Black bar: 100 μ m.

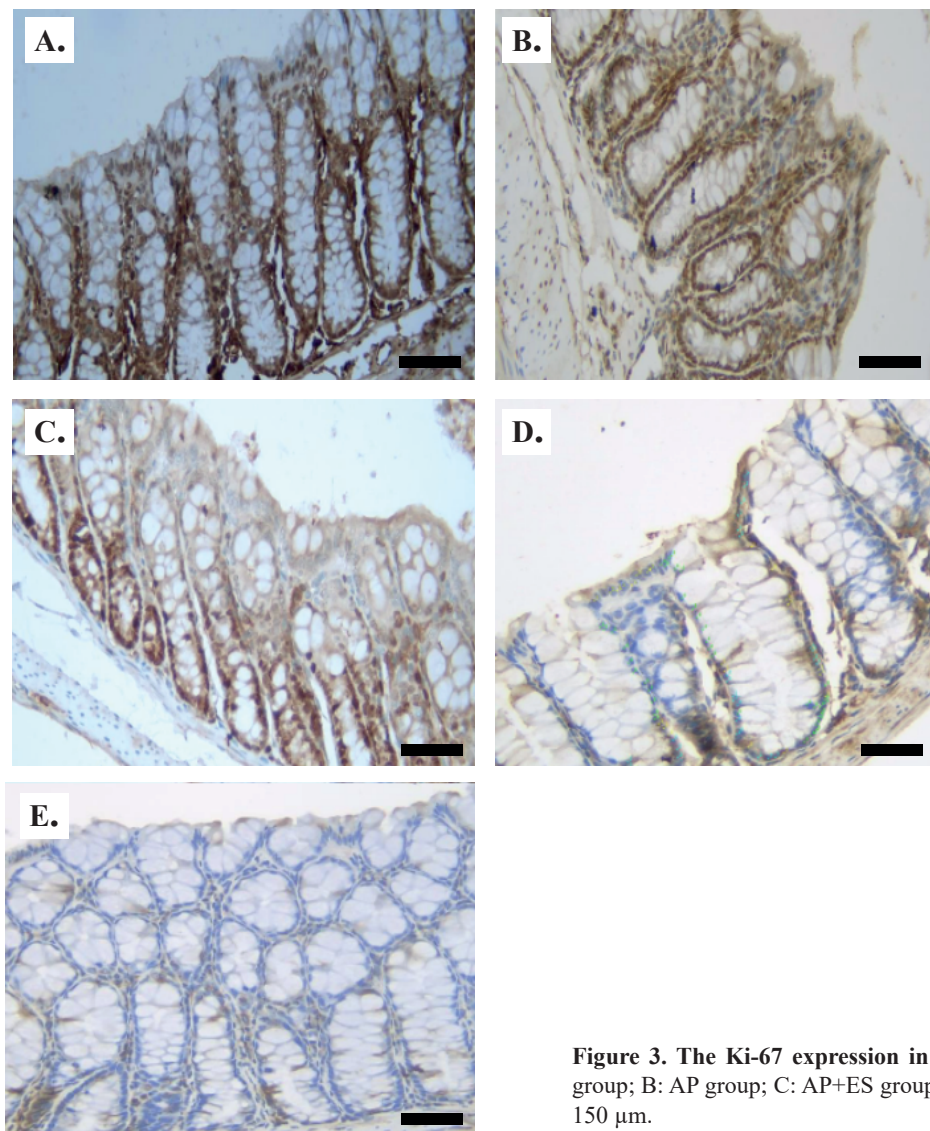


Figure 3. The Ki-67 expression in the colonic epithelial cells. A: CMC group; B: AP group; C: AP+ES group; D: DHP group; E: AP+PS. Black bar: 150 μ m.

significant differences in terms of angiogenesis, dysplasia, and the number of goblet cells.(4) The extract dosage can still be increased up to 300 mg/kgBW. Higher doses are not recommended for long term administration because of the hemolytic effect due to increased water transport through aquaporins by saponin induction.(23)

Phycocyanin and other active compounds of *S. platensis* acts as antioxidants, anti-inflammatory, and anti-tumor agents.(24,25) This was evidenced by the expression of Ki-67 in the AP+PS group which was significantly lower than the AP group. However, the difference in Ki-67 expression in the AP+ES group and the AP group compared to the CMC control group was not statistically significant. The difference between the two dosage forms of *S. platensis* can be caused by the presence of water-soluble active substances contained in the powder preparation, but not possessed by the ethanolic extract. That way, powder preparations are more effective than ethanolic extract preparations. While this study proved that combination therapy of *A. paniculata* and *S. platensis* powder works better than monotherapy of *A. paniculata* extract, whether the effects of these herbal agents were synergistic or antagonistic should further be analyzed. Hence, it is necessary to have further study with additional test groups that are only given *S. platensis* extract and/or powder to determine the efficacy of *S. platensis* herbal ingredients alone without the influence of *A. paniculata* extract.

Conclusion

Although not significant, but the administration of 70% *A. paniculata* extract at a dose of 200 mg/kgBW/day and *S. platensis* powder at a dose of 130 mg/kgBW/day for 28 days can reduce the expression of Ki-67 on colonic epithelial cells of mice infected with *P. berghei*. This is equivalent to the effect of DHP therapy at a dose of 195 mg/kgBW/day for 4 days. Therefore, the combination of *A. paniculata* and *S. platensis* is able to reduce the proliferation as a result of prolonged inflammation in malarial infection.

Acknowledgements

The author thanks the Directorate of Research and Development, Universitas Indonesia, thanks to the Animal Laboratory Research and Development Agency, Ministry of Health, Jakarta. This study was funded by The Directorate

of Research and Development, Universitas Indonesia (PUTI 2020).

Authors Contribution

KK, NSL, TWL, and PRI were involved in conceiving and planning the research, BA and NSL performed the data acquisition/collection, BA and TWL calculated the experimental data and performed the analysis, BA and PRI drafted the manuscript and TWL and PRI designed the figures, KK, TWL, PRI, and AP aided in interpreting the results. KK, TWL, PRI and AP took parts in giving critical revision of the manuscript.

References

1. World Health Organization. World Malaria Report 2018. Geneva: World Health Organization; 2018.
2. Masrizal M, Putri T, Hasni I. Environmental and behavioral conditions that affect malaria events in padang city. *J Berk Epidemiol*. 2020; 8(2): 164–71.
3. Enns R, Bressler B. Dysplasia and colitis. *Can J Gastroenterol J Can Gastroenterol*. 2009; 23(5): 345–7.
4. Kusmardi K, Jabir R, Wisnubaroto R, Firzani D. The combination of *Spirulina* extract and Sambiloto effect histopathologically on medial colon from *Plasmodium berghei* Anka infected mice. *Pharmacogn J*. 2019; 11(3): 564–9.
5. World Health Organization. Guidelines for the Treatment of Malaria. 3rd ed. Geneva: World Health Organization; 2015.
6. Ouji M, Augereau JM, Paloque L, Benoit-Vical F. *Plasmodium falciparum* resistance to artemisinin-based combination therapies: A sword of Damocles in the path toward malaria elimination. *Parasite Paris Fr*. 2018; 25: 24. doi: 10.1051/parasite/2018021.
7. Woodrow CJ, White NJ. The clinical impact of artemisinin resistance in Southeast Asia and the potential for future spread. *FEMS Microbiol Rev*. 2017; 41(1): 34–48.
8. Nsanabana C. Resistance to artemisinin combination therapies (ACTs): do not forget the partner drug!. *Trop Med Infect Dis*. 2019; 4(1): 26. doi: 10.3390/tropicalmed4010026.
9. Deng R, Chow TJ. Hypolipidemic, antioxidant, and antiinflammatory activities of microalgae *Spirulina*. *Cardiovasc Ther*. 2010; 28(4): e33–45.
10. Ali EAI, Barakat BM, Hassan R. Antioxidant and angiostatic effect of *Spirulina platensis* suspension in complete Freund's adjuvant-induced arthritis in rats. *PloS One*. 2015; 10(4): e0121523. doi: 10.1371/journal.pone.0121523.
11. Okhwarobo A, Falodun JE, Erharuyi O, Imieje V, Falodun A, Langer P. Harnessing the medicinal properties of *Andrographis paniculata* for diseases and beyond: a review of its phytochemistry and pharmacology. *Asian Pac J Trop Dis*. 2014; 4(3): 213–22.
12. Dhiman A, Goyal J, Sharma K, Nanda A, Dhiman S. A review of medicinal prospectives of *Andrographis Paniculata* Nees. *J Pharm Sci Innov*. 2012; 1: 1–4.
13. Kusmardi K, Elya B, Wahyuni T, Paramita RI. Combination of sambiloto (*Andrographis paniculata* (Burm.F.) nees) extract and

- spirulina (*Arthrospira platensis* gomont) to prevent anemia in mice infected with *Plasmodium berghei* anka. *Asian J Pharm Clin Res.* 2017; 10: 269. doi: 10.22159/ajpcr.2017.v10i12.21231.
14. Li LT, Jiang G, Chen Q, Zheng JN. Ki67 is a promising molecular target in the diagnosis of cancer (review). *Mol Med Rep.* 2015; 11(3): 1566–72.
 15. Zeng H, Umar S, Rust B, Lazarova D, Bordonaro M. Secondary bile acids and short chain fatty acids in the colon: a focus on colonic microbiome, cell proliferation, inflammation, and cancer. *Int J Mol Sci.* 2019; 20(5): 1214. doi: 10.3390/ijms20051214.
 16. Huang BW, Pearman E, Kim CC. Mouse models of uncomplicated and fatal malaria. *Bio-Protoc.* 2015; 5(13): e1514. doi: 10.21769/bioprotoc.1514.
 17. Déchamps S, Maynadier M, Wein S, Gannoun-Zaki L, Maréchal E, Vial HJ. Rodent and nonrodent malaria parasites differ in their phospholipid metabolic pathways. *J Lipid Res.* 2010; 51(1): 81–96.
 18. Mawson AR. The pathogenesis of malaria: a new perspective. *Pathog Glob Health.* 2013; 107(3): 122–9.
 19. Taniguchi T, Miyauchi E, Nakamura S, Hirai M, Suzue K, Imai T, *et al.* *Plasmodium berghei* ANKA causes intestinal malaria associated with dysbiosis. *Sci Rep.* 2015; 5(1): 15699. doi: 10.1038/srep15699.
 20. Marwa KJ, Konje ET, Kapesa A, Kamugisha E, Mwita S, Swedberg G. Artemether-lumefantrine and dihydroartemisinin-piperaquine treatment outcomes among children infected with uncomplicated *Plasmodium falciparum* malaria in Mwanza, Tanzania. *Trop Med Health.* 2021; 49(1): 94. doi: 10.1186/s41182-021-00383-3.
 21. Landén NX, Li D, Stähle M. Transition from inflammation to proliferation: a critical step during wound healing. *Cell Mol Life Sci CMLS.* 2016; 73(20): 3861–85.
 22. Cuylen-Haering S, Petrovic M, Hernandez-Armendariz A, Schneider MWG, Samwer M, Blaukopf C, *et al.* Chromosome clustering by Ki-67 excludes cytoplasm during nuclear assembly. *Nature.* 2020; 587(7833): 285–90.
 23. Yang LL, Zhou QJ, Wang Y, Gao Y, Wang YQ. Comparison of the therapeutic effects of extracts from *Spirulina platensis* and amnion membrane on inflammation-associated corneal neovascularization. *Int J Ophthalmol.* 2012; 5(1): 32–7.
 24. Niljan J, Jaihan U, Srichairatanakool S, Uthaipibull C, Somsak V. Antimalarial Activity of Stem Extract of *Tinospora Crispa* against *Plasmodium Berghei* Infection in Mice. *J Health Res.* 2014; 28(3): 199–204.
 25. Gaur P. Evaluation of safety aspects of *Andrographis paniculata* in Swiss-albino mice at sub acute level. *IAMJ.* 2014; 2(5): 681–6.